

Treatment of telangiectasia using the multi-pass technique with the extended pulse width, pulsed dye laser (Cynosure V-Star)

Emil Tanghetti & Evan A Sherr

Authors:

Emil Tanghetti, MD
Sacramento, CA, USA

Evan A Sherr, MS
Cynosure, Inc., Chelmsford, MA,
USA

Received 7 January 2003

Accepted 7 January 2003

Keywords:

facial veins – leg veins – purpura –
selective photothermolysis

BACKGROUND: The pulsed dye laser (PDL) has been used for the treatment of facial and leg telangiectasia, where it provides safe and effective treatment. Often, a single treatment with the PDL can provide acceptable vessel clearance. Unfortunately, the hallmark of PDL treatment is transient purpura, which can be cosmetically unacceptable to patients. A new class of PDL has been developed in an effort to reduce this transient side effect while maintaining both safety and efficacy.

OBJECTIVE: To evaluate the ability of multi-pass treatment for telangiectasia with extended pulse width (40 ms) PDL to provide effective, single-treatment vessel treatment without inducing purpura.

METHODS: A total of 40 patients presenting with facial or leg telangiectasia were treated with the extended pulse width PDL (595 nm), used in conjunction with refrigerated air-cooling (SmartCool; Cynosure). Treatment was given using a pulse width of 40 ms and fluences at or below the purpuric threshold (less than 16 J/cm²) and with high-flow air cooling at -4°C. Up to three passes were given until vessel disappearance or intravascular coagulation was observed. A second treatment was

done, where needed, 4-8 weeks following the initial treatment. Patients were evaluated 4, 8, and 12 weeks after the final treatment.

RESULTS: Following a single treatment, 70% of facial and 80% of leg vessels exhibited at least 75% clearance. After two treatments, 14/20 leg vessels cleared at 75-100%. In all cases, vessel clearance was associated with transient purpura lasting less than 7 days. Hyperpigmentation occurred in 5% of facial vessels and 55% of leg veins. Sub-purpuric doses did not provide acceptable single-treatment clearance.

CONCLUSIONS: Extended pulse width dye lasers significantly increase the threshold for purpura, allowing higher fluences to be employed. For the goal of single treatment vessel clearance, the extended pulse duration provided acceptable, single-treatment improvement but only in the presence of purpura. While additional, non-purpuric treatments may provide acceptable outcomes, additional improvements will be necessary to provide consistent, effective, single-treatment clearance of telangiectasia without generalized purpura. J Cosmetic & Laser Ther 2003; 5: 71-75

Introduction

The treatment of vascular lesions was revolutionized with the concept of selective photothermolysis and the ability to target blood vessels selectively, reducing the risk of damage to surrounding structures.^{1,2} The judicious choice of complimentary wavelength, pulse width, and fluence has the potential to provide exquisite therapeutic control. Since its introduction 20 years ago, the pulsed dye laser (PDL) has established an exemplary record for treatment safety and efficacy.³⁻⁶ The PDL is now used for the treatment of vascular lesions in structures as critical and delicate as the vocal folds.⁷

In addition to the therapeutic treatment of vascular lesions, the PDL has been used for the treatment of telangiectasia of the face and legs. While PDL treatment requires fewer treatments for clearance,⁸⁻¹¹ and has a superior side-effects profile compared with other treatment methods, the common side effect of purpura is an impediment to widespread adoption for general cosmetic use.^{11,12} Pigmentation is frequent on lower leg lesions following PDL treatment.

Traditional PDLs have typically used pulse durations from 0.45 to 1.5 ms, designed for the treatment of port wine birthmarks. These pulse durations are well suited to the treatment of smaller vessels, from 0.03 to 0.3 mm in diameter.¹³ These parameters, at clinically relevant fluences, also cause damage to small, surrounding capillary structures, resulting in purpura.¹⁴ While it may be possible to produce acceptable clearance without purpura, the methods required, such as multiple repeated laser exposures at sub-purpuric fluences,¹⁵ are unacceptable to both physician and patient in the clinic setting.

Telangiectasia is typically associated with vessels between 0.2 and 1 mm in diameter. According to Dierickx, these vessels are better targeted with longer pulse durations, in the range of at least 1–10 ms.¹⁶ This creates new opportunities to modify the PDL in such a manner that it may provide effective treatment for this class of vessel while reducing or eliminating purpura. Modeling of the PDL laser-tissue interaction at longer pulse durations suggests that a single pulse with a duration over 3 ms will provide damage to vessels over 200 μm in diameter while sparing smaller, purpurogenic vessels, even at the higher fluences required for effective vessel clearance with longer pulse durations (M Mirkov, unpublished communication, 2002). Unfortunately, current PDL technology cannot provide a single pulse of sufficient duration.

Instead, a new generation of PDLs has been developed which use a train of closely spaced pulse-lets, which attempt to mimic a continuous extended pulse. These systems use a string of either $3 \times 250 \mu\text{s}$ or $4 \times 150 \mu\text{s}$ pulse-lets for their extended pulse formats.^{13,14} Using this technique results in a PDL capable of producing extended pulse durations in the order of 3–40 ms.

The treatment of telangiectasias in the cosmetic patient requires stringent criteria for success. Optimally, successful treatment would provide single treatment elimination of every treated vessel with no purpura and no side effects; however, this is not realistic. To gain broad acceptance we

set a stringent success criteria for laser treatment of telangiectasia to provide the following:

- the safety profile of traditional PDL
- effective, consistent, single-treatment clearance in the majority of treatments
- elimination of generalized purpura in the majority of treatments.

These systems have been able to reduce the intensity and duration of purpura at clinically effective doses. Our experience using traditional PDL techniques with the three pulse format mirrors the experience reported by Gerone-mous with the four pulse format: no consistent, single-treatment clearance unless some purpura is induced.¹⁵

In an effort to improve the performance of the extended pulse formats, we investigated the use of multiple passes in conjunction with extended pulse formats with the goal of meeting all the criteria described above.

Methods

A total of 40 patients (eight male, 32 female) were recruited for the study. In all, 20 patients presented with facial and 20 with leg telangiectasia consisting of diameters ranging from 0.1 to 1.2 mm in diameter. All individuals provided informed consent prior to treatment. Prior to treatment, patients were tested to determine their purpuric threshold, which was then used as a guide for treatment. The treatment areas were also photographed to provide a baseline for determination of treatment efficacy.

Treatments were done using a PhotoGenica V-Star PDL (Cynosure Inc., Chelmsford, MA, USA) set up at a 595-nm wavelength. All treatments were done using adjunctive cold air-cooling (SmartCool, Cynosure Inc.). The PhotoGenica V-Star uses a three-pulse-let format for extended pulse durations.¹⁷ All treatments were done using a 7-mm handpiece at fluences ranging from 14 to 16 J/cm², depending on the patient's purpuric threshold. Treatment of telangiectasia consisted of single pulses at 1 Hz at or below the single pulse purpuric threshold, typical use 1 and 2 passes and sometimes 3 passes until vessel disappearance or intra-vascular coagulation was observed (Figure 1).

Following treatment, patients followed standard post-care instructions. Patients were also to report any side effects immediately.

Patients returned 1 month following initial treatment for evaluation, photographs, and additional treatment, as required, using the treatment parameters described above. In addition, patients returned for follow-up evaluation 1 and 2 months and 1 year following the final treatment.

Analysis of results was based on subjective evaluation of pre- and post-treatment photographs, determination of degree and duration of purpura or any other side effects and, in the case of facial telangiectasia, the number of treatments required to achieve vessel clearance. Vessel clearance was rated on a scale of 0–25%, 26–50%, 51–75%, and 76–100%. This study included very stringent criteria for success: acceptable vessel clearance was defined as either complete clearance of 75% or greater of treated vessels, or 75% or greater fading

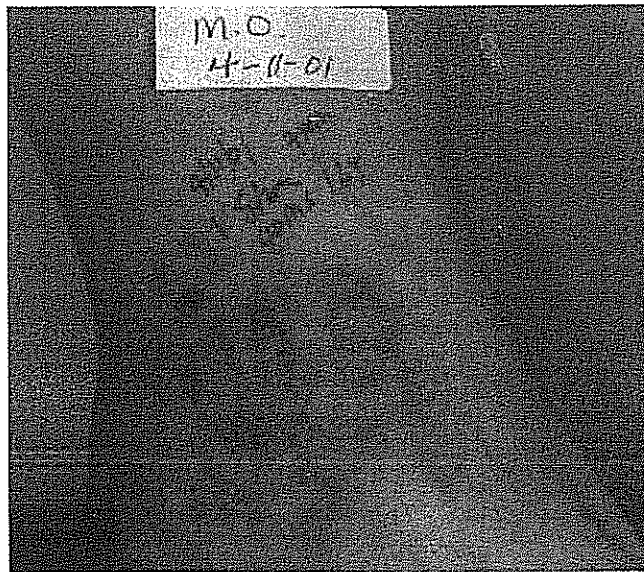


Figure 1
Typical treatment endpoint following treatment with one to three passes at a 40-ms pulse duration and fluence of 16 J/cm²

of all treated vessels. In addition, complete success was defined as no purpura and no adverse effects.

Results

Results are separated into facial and leg telangiectasia, as these provided different outcomes.

Facial telangiectasia

Following a single treatment session, 80% (16 of 20) exhibited 75–100% clearance of facial vessels (Table 1). The

	Per cent clearance				Total
	0–25%	26–50%	51–75%	76–100%	
2 months post treatment 1	0	0	4	16	20
2 months post treatment 2	0	0	0	20	20

Table 1
Clearance rates of facial vessels between 0.2 and 1.0 mm in diameter treated with one to three passes at 14–16 J/cm² fluence and a 40-ms pulse duration using cold-air cooling.

remaining 20% (four of 20) exhibited 50–75% clearance. In all cases, this was associated with some mild, reddish purpura lasting 5–7 days. Treatment was associated with mild discomfort, which did not require anesthesia beyond that provided by cold air-cooling. No other side effects were reported (Table 2).

Two months following a second treatment in those who did not achieve complete clearance, 100% (20 of 20) exhibited 75–100% clearance of leg vessels (Figure 2). Again, transient purpura lasting 5–7 days was associated with vessel clearance. Five per cent (one of 20) exhibited hyperpigmentation lasting more than 2 months. In one case, Q-switch ruby laser treatment was required to clear hyperpigmentation lasting more than 6 months. No other side effects other than discomfort during treatment were noted (Table 2).

Leg telangiectasia

Following a single treatment session (Table 3), 70% (14 of 20) exhibited 75–100% clearance of leg vessels; 15% (three of 20) exhibited 50–75% clearance; 5% (one of 20) exhibited 25–50% clearance; and 10% (two of 20) exhibited 0–25% clearance (Figure 3). In all cases, this was associated with some purpura lasting 5–7 days. A total of 55% (11 of 20) experienced hyperpigmentation lasting more than 4 months and 10% (two of 20) exhibited neovascularization at the site of treatment. Treatment was associated with mild discomfort, which did not require anesthesia beyond that provided by cold air-cooling. No patients experienced crusting or scarring (Table 2).

In several cases, purpura, which was absent or minimal shortly after treatment, became more pronounced within 24 hours.

Discussion

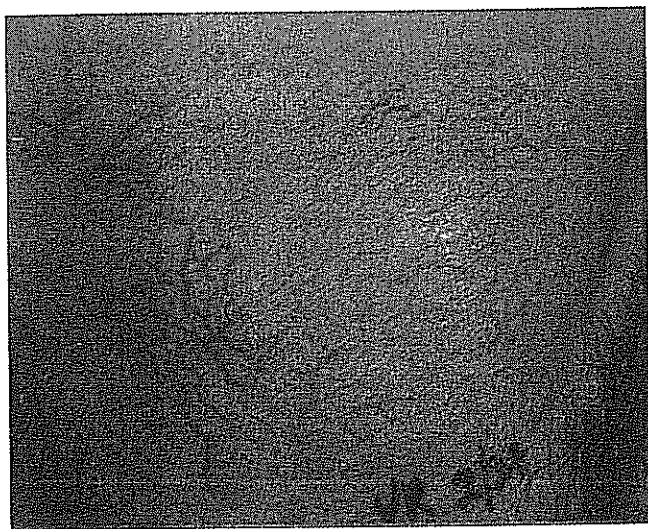
The goal of this study was to develop a technique that would provide effective, consistent, single-treatment clearance in the majority of treatments while retaining the safety profile of traditional PDL, without the induction of purpura.

The use of refrigerated cooling with a 40-ms PDL and the single or multiple pass treatment facilitated the clearance of facial and leg telangiectasia. However, to achieve consistent clearance in one to two treatment sessions, treatment fluences that induced purpura were required. While it may be possible to achieve clearance in some patients, using some techniques without purpura, this was the exception rather than the rule.

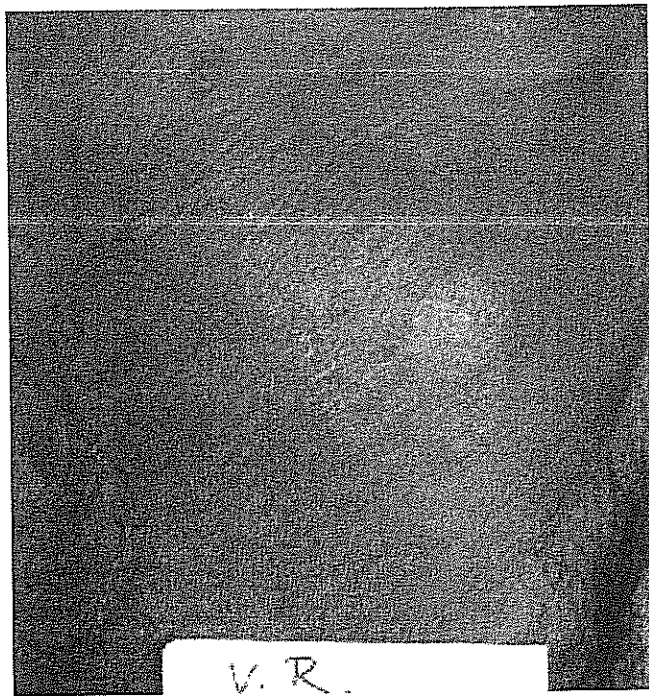
	Side effect					
	Purpura	Crusting	Hyper-pigmentation	Scarring	Neo-vascularization	Discomfort
Facial treatment 1	20/20	0/20	0/20	0/20	0/20	20/20
Facial treatment 2	20/20	0/20	1/20	0/20	0/20	20/20
Leg treatment	20/20	0/20	11/20	0/20	2/20	20/20

Table 2
Side effects of PDL treatment of facial and leg veins using a 40-ms pulse duration and cold-air cooling.

Review



(A)



(B)


Figure 2

Typical clearance of facial vessels following two treatments using one to three passes at a 40-ms pulse duration and fluence of 14–16 J/cm² (A) prior to treatment and (B) 2 months following two treatments


	Per cent clearance				Total
	0–25%	26–50%	51–75%	76–100%	
2 months post treatment	2	1	3	14	20

Table 3

Clearance rates of leg veins between 0.2 and 1.0 mm in diameter treated with one to three passes at 14–16 J/cm² fluence and a 40-ms pulse duration using cold-air cooling.



(A)



(B)

Figure 3

Typical clearance of leg veins following treatment using one to three passes at a 40-ms pulse duration and fluence of 14–16 J/cm² (A) prior to treatment and (B) 2 months following treatment

The side-effects profile of this treatment was similar to that with traditional PDL. The purpura produced with extended pulse durations was less intense than our experience with short pulse durations, and resolved in about half the time. Hyperpigmentation was a consistent finding in the treatment of leg telangiectasia for those with all treated skin types, and appeared to be related to anatomy and physiology rather than skin type. However, this experience was no different than using traditional methods. With the use of high fluences, extended pulse durations, and multiple passes, the patients did not experience any scarring, suggesting that this procedure retains the safety of traditional PDL application.

The 40-ms pulse width offers an effective treatment for larger vessels up to 1 mm on the face and legs. However, this technique did not meet the criteria for success: single-treatment clearance without purpura. Owing to the configuration of the pulse train in the current long

pulse PDLs, we doubt that purpura-free treatment can reliably be performed in one to two treatment sessions

without further development of PDL technology to meet the stringent criteria suggested.

References

1. Anderson RR, Parrish JA. Microvasculature can be selectively damaged using dye lasers: a basic theory and experimental evidence in human skin. *Lasers Surg Med* 1981; 1: 263–76.
2. Anderson RR, Parrish JA. Selective photothermolysis: precise microsurgery by selective absorption of pulsed radiation. *Science* 1983; 220: 524–7.
3. Tan OT, Sherwood K, Gilchrist BA. Treatment of children with port-wine stains using the flashlamp-pulsed tunable dye laser. *N Engl J Med* 1989; 320: 416–21.
4. Garden JM, Bakus AD. Clinical efficacy of the pulsed dye laser in the treatment of vascular lesions. *J Dermatol Surg Oncol* 1993; 19: 321–6.
5. Levine VJ, Geronemus RG. Adverse effects associated with the 577- and 585-nanometer pulsed dye laser in the treatment of cutaneous vascular lesions: a study of 500 patients. *J Am Acad Dermatol* 1999; 41: 100–2.
6. Glassberg E, Lask G, Rabinowitz LG, Tunnessen WW. Capillary hemangiomas: case study of a novel laser treatment and a review of therapeutic options. *J Dermatol Surg Oncol* 1989; 15: 1214–23.
7. Franco RA, Zeitels SM, Faranelli WA, Anderson RR. 585-nm pulsed dye laser treatment of glottal papillomatosis. *Ann Otol Rhinol Laryngol* 2002; 111: 486–92.
8. Buscaglia DA, Conte ET. Successful treatment of generalized essential telangiectasia with the 585-nm flashlamp-pulsed pulsed dye laser. *Cutis* 2001; 67: 107–8.
9. Reichart D. Evaluation of the long-pulse dye laser for the treatment of leg telangiectasias. *Dermatol Surg* 1998; 24: 737–40.
10. Tan E, Vinciullo C. Pulsed dye laser treatment of telangiectasia. *Australas J Dermatol* 1997; 38: 22–5.
11. West TB, Alster TS. Comparison of the long-pulse dye (590–595-nm) and KTP (532-nm) lasers in the treatment of facial and leg telangiectasia. *Dermatol Surg* 1998; 24: 221–6.
12. Travelute Ammirati C, Carniol PJ, Hruza GJ. Laser treatment of facial vascular lesions. *Facial Plast Surg* 2001; 17: 193–201.
13. Kimel S, Svaasand LO, Cao D et al. Vascular response to laser photothermolysis as a function of pulse duration, vessel type, and diameter: implications for port wine stain laser therapy. *Lasers Surg Med* 2002; 30: 160–9.
14. Arndt KA, Dover JS. *Controversies & conversations in cutaneous laser surgery*. AMA Press, USA. 2002: 125–7.
15. Diericks CC, Farinelli WA, Anderson RR. Multiple-pulse photocoagulation of portwine stain blood vessels (PWS) with the 585 nm pulsed dye laser. *Lasers Surg Med* 1995; Suppl 17: 56 (abstr).
16. Dierickx CC, Casparian JM, Venugopalan V et al. Thermal relaxation of port-wine stain vessels probed in vivo: the need for 1–10-millisecond laser pulse treatment. *J Invest Dermatol* 1995; 105: 709–14.
17. Tanghetti E et al. Evaluation of pulse-duration on purpuric threshold using extended pulse pulsed dye laser (Cynosure V-Star). *Lasers Surg Med* 2003 (in press).
18. Geronemus RG, Lou WW. “Treatment of port wine stains by variable pulse width pulse dye laser with cryogen spray”. “A Preliminary Study” *Dermatology Surg* 2001; 27: 903–6.